

# Early visual cortex organization in autism: an fMRI study

Nouchine Hadjikhani,<sup>CA</sup> Christopher F. Chabris,<sup>1</sup> Robert M. Joseph,<sup>2</sup> Jill Clark,<sup>2</sup> Lauren McGrath,<sup>2</sup> Itzhak Aharon,<sup>1</sup> Eric Feczko,<sup>2</sup> Helen Tager-Flusberg<sup>2</sup> and Gordon J. Harris<sup>3</sup>

Martinos Center for Biomedical Imaging, Massachusetts General Hospital, Harvard Medical School, Bldg. 36, First Street, Room 417, Charlestown, MA 02129;

<sup>1</sup>Department of Psychology, Harvard University, Cambridge, MA 02138; <sup>2</sup>Boston University School of Medicine; <sup>3</sup>Radiology Computer Aided Diagnostic Laboratory, Massachusetts General Hospital, Boston, MA, USA

<sup>CA</sup>Corresponding Author: nouchine@nmr.mgh.harvard.edu

Received 26 August 2003; accepted 20 October 2003

DOI: 10.1097/01.wnr.0000107523.38715.fa

Autism is a neurodevelopmental disorder characterized by preserved visual abilities as well as a special profile for visual cognition. We examined the visual cortex of high-ability individuals with autism in order to assess whether the presence of abnormalities at the primary sensory level in autism could be the basis of their unusual pattern of visual cognitive abilities. We found that the early sensory visual areas are normally organized in individuals with

autism, with a normal ratio between central versus peripheral visual field representation. We conclude that the differences observed in the visual capacities of individuals with autism are likely to arise from higher-level cognitive areas and functions, and are the result of top-down processes. *NeuroReport* 15:267–270 © 2004 Lippincott Williams & Wilkins.

**Key words:** Asperger syndrome; Autism; Brain imaging; Retinotopy; Visual processing

## INTRODUCTION

Abnormalities of sensory processing have long been suspected to play a role in autism. On one hand, low-level visual impairment can lead to autistic-like behavior [1]; on the other hand, individuals with autism present an idiosyncratic profile of visuo-perceptive and visuo-spatial functions as well as related behaviors and features, such as the tendency to be overly attentive to and distressed by small changes of minor features of their visual environment. Whether this profile arises from atypical visual perception abilities has been a long-standing question.

In this study, we addressed the question of whether these autism-related behavioral idiosyncrasies in visual cognition and behavior are related to low-level (bottom-up) processing differences, or whether they arise from higher-level abnormalities in top-down attentional or cognitive processes. Individuals with autism show superior performance compared with normal controls in a variety of perceptual tasks that involve the visual system. For example, they tend to perform better at tasks that demand a highly acute perception of features, such as the Block Design subtest of the Wechsler Intelligence scale [2,3] or the embedded figures test [4,5]. When asked to copy a figure, they produce more local features at the start of copying compared with normal controls [6,7]. Individuals with autism also exhibit superior visual search relative to normal controls [8]. They are also impaired in identifying visual illusions ([9], but see [10]) and impossible figures [7]. The local processing efficiency in individuals with autism raises the question of the origin of

their higher discriminative skills. The visual cortex is organized in increasingly complex areas. Visual information is transmitted from the retina to the primary visual cortex (V1) via the lateral geniculate nucleus. From there, it is distributed to extrastriate areas, and to more and more complex visual areas involved in cognitive processes, such as object and face recognition, visuo-spatial abilities and attention allocation. In the early visual cortices, it is known that local and global attention are mapped retinotopically [11]. Local attention is processed in the part of the cortex where the foveal representation of the visual field is represented, whereas global attention activates the part of the cortex devoted to more peripheral representation of the visual field. Researchers investigating local/global bias in autism [4,6,7,12] have brought into question the representation of local and global attention, and the possible role of alternative cognitive strategies [13]. The weak central coherence hypothesis has been one of the dominant explanations of the autistic behavior for over the past 10 years ([14], but see [15]). This hypothesis states that the lack of integration of information leads to perceptual and attentional deficits in autism. The weak central coherence could emerge from an overrepresentation of the central visual field relative to the periphery. So far, the mechanism responsible for this lack of integration has not been identified. In this study, we examined whether the early stages of visual processing could account for this effect. More specifically, we examined whether the central versus the peripheral representation of the visual field is different

**Table 1.** Participant characteristics.

	Autism spectrum (n=8)		Control (n=4)	
	Mean $\pm$ s.d.	Range	Mean $\pm$ s.d.	Range
Age (years)	35 $\pm$ 12	18–52	24 $\pm$ 2	21–25
Full Scale IQ	117 $\pm$ 6	110–128	117 $\pm$ 3	114–120
Verbal IQ	120 $\pm$ 8	106–131	118 $\pm$ 10	107–131
Performance IQ	110 $\pm$ 9	95–119	113 $\pm$ 14	96–129

in individuals with autism compared with normal controls. Using the same stimuli as those we and others have been using successfully to map the visual cortex of normal subjects [16–19], we examined the organization of the visual cortex in 8 adult individuals with autism. We assessed whether abnormalities in early sensory areas might explain the idiosyncrasies observed in visual processing in autism, or whether higher-level cognitive brain areas would be more likely to account for these differences.

## MATERIAL AND METHODS

Participants were eight high-ability individuals with autism spectrum disorder (ASD) (including autism Asperger syndrome, or pervasive development disorder not otherwise specified-PDD-NOS) and four non-autistic controls, who were matched on Full Scale, Verbal, and Performance IQ, as measured on the Wechsler Abbreviated Scale of Intelligence [20] (Table 1). The clinical diagnoses of individuals in the autism spectrum group were confirmed using the Autism Diagnostic Interview-Revised (ADI-R; [21]), a parent interview which yields ratings for social, communication, and repetitive behaviors symptoms based primarily on behaviors reported for the 4–5 year age period, and/or the Autism Diagnostic Observation Schedule (ADOS; [22]), a behavioral observational instrument which assesses autism symptoms in the social and communication domains. On the ADOS, 2 participants met criteria for autism and the remaining 6 for ASD (either Asperger or PDD-NOS). On the ADI-R, 3 participants met criteria for autism and 4 for ASD; a reliable informant was not available for one of the participants, however he met ADOS criteria for autism.

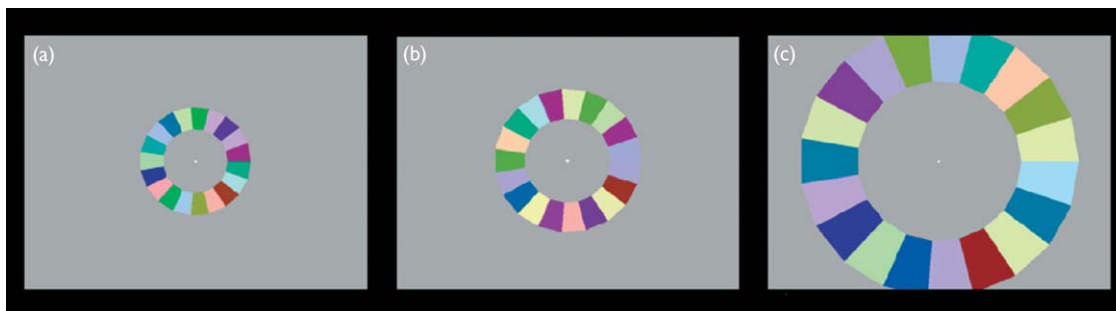
Informed written consent was obtained for each participant before the scanning session, and all procedures were approved by the Massachusetts General Hospital Human Studies Committee under Protocol 1999-P-010976/12. Structural scans were obtained in a Siemens 1.5 T and MR images of brain activity were collected in a high field Siemens 3.0 T high-speed echoplanar imaging device (Munich) using a quadrature head coil. Subjects laid on a padded scanner couch in a dimly illuminated room and wore foam earplugs. Foam padding stabilized the head. High-resolution ( $1.0 \times 1.0 \times 1.3$  mm) structural images were obtained for 3D reconstruction using a magnetization-prepared rapid acquisition with gradient echoes (MP-RAGE) pulse sequence, (128 slices;  $256 \times 256$  matrix; echo time (TE)=3.44 ms; repetition time (TR)=2730 ms; flip=7°). They were segmented, reconstructed, inflated and flattened [23] using FreeSurfer (<http://surfer.nmr.mgh.harvard.edu>). Functional sessions began with an initial sagittal localizer scan, followed by autoshimming to maximize field homogeneity. To register functional data to the 3D reconstructions, a set of

high-resolution (44 coronal slices, perpendicular to the calcarine sulcus,  $1.5 \times 1.5$  mm in-plane  $\times$  4 mm thick, no skip) inversion time T1-weighted echo-planar images (TE=29 ms; TI=1200 ms; TR=6000 ms; number of excitations (NEX)=4) was acquired, along with T2 conventional high-resolution anatomical scans ( $256 \times 256$  matrix, TE=104 ms; TI=1200 ms; TR=11 s; NEX=2). The co-registered functional series (TR=4000 ms; 128 images per slice; TE=30 ms, flip angle 90°; FOV=20  $\times$  20 cm, matrix=64  $\times$  64; in-plane resolution  $3.125$  mm<sup>2</sup>) lasted 512 s. Retinotopic eccentricity was mapped by presenting phase-encoded, expanding rings of checks (Fig. 1) going through eight 64 s expansion from central (0.75°) through peripheral (15°) eccentricities in repeating cycles. The checks changed randomly and independently in both color (within the range of the LCD projector) and luminance ( $\sim 1$ –140 cd/m<sup>2</sup>). A full expansion cycle took 64 s, and each scan took 8 min 32 s (8 cycles). Check size and expansion speed were scaled approximately logarithmically, and the colored checks flickered continuously at  $\sim 2$  Hz throughout the scan. Visual areas V1, V2, V3, VP, V3A, V4v and V8 were distinguished by combining the phase-encoded tests of retinotopic eccentricity and polar angle [16,18,19,24,25]. Subjects were instructed to fixate on a small cross in the center of the screen and not to move their eyes from this fixation point. Each of functional runs was motion-corrected by using AFNI (<http://afni.nimh.nih.gov/afni/index.shtml>). Statistical maps were calculated in the following way: a fast Fourier transform was performed on the time course of each voxel. Then the ratio of the signal power at the fundamental stimulus frequency and average power at all frequencies was computed, excluding the first and second harmonics and very low frequencies (1–3 cycles/scan). Under the assumption of white (temporally uncorrelated) noise, the power at each frequency is an independent, identically distributed chi-square random variable, and so the resulting ratio of signal power is F-distributed. On this basis, the significance of the activation at each voxel was determined using an F-statistic.

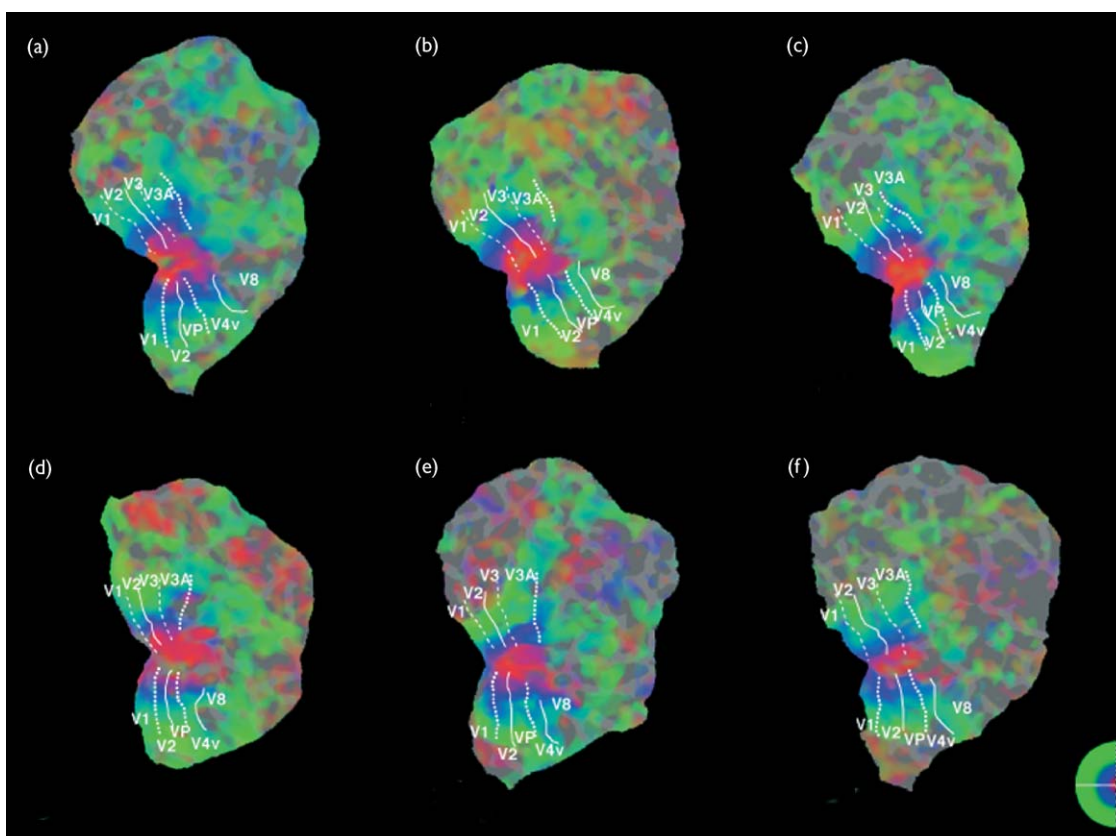
## RESULTS

Maps of retinotopic organization were obtained in all participants with autism. They did not differ by their quality or their organization from maps obtained from normal controls in this and from numerous previous studies conducted in our group [11,18,19]. The representation of the foveal and the peripheral parts of the visual field was similar between the individuals with autism and the normal controls.

No qualitative difference in activation could be seen between the brains of our participants with autism and the brains of our normal controls. In both populations, the representation of eccentricity was similar, not showing an



**Fig. 1.** Three snapshots of the eccentricity stimulus we used, taken at different times. The stimulus is comprised of flickering checks which are scaled in size to take into account cortical magnification factor. A small fixation cross in the center is present at all times.



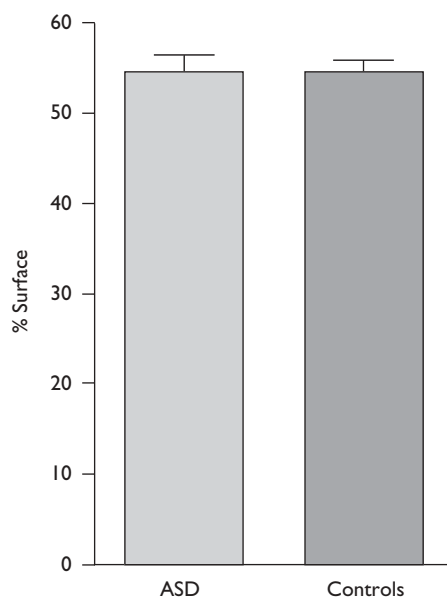
**Fig. 2.** Retinotopic eccentricity maps of three subjects with autism (a–c) and three controls (d–f). The data are represented in flattened cortical format, in six different right hemispheres. The location of visual cortical areas V1, V2, V3/VP, V3A, V4v and V8 is labeled for comparison; dotted white lines = upper vertical meridian, dashed white lines = lower vertical meridian, solid white lines = horizontal meridian. In this pseudocolor format (see logo on the bottom right), retinotopically specific modulation appear in red, green, or blue (centered approximately at eccentricities 1.5, 3.8 and 10.3°, respectively). It is scaled logarithmically, in accord with the cortical magnification factor.

enhanced representation for the foveal part of the visual field. In order to quantify the lack of difference between autistic subjects and normal controls, we defined on the flattened surface (Fig. 2) regions of interest mapping the central foveal and the peripheral visual field representation. We measured the surface of these two regions of interest, in the 16 hemispheres of participants with autism and 16 hemispheres of normal controls (from this and our previous studies), and looked at the percentage of cortex that represents the fovea (Fig. 3). No significant difference could be seen between the participants with

autism and the normal controls ( $p=0.9835$ , two-sided, two-sampled *t*-test).

## DISCUSSION

During functional scanning, participants with autism showed a high level of focused attention. In order to obtain good retinotopic maps, it is mandatory that the same image falls on the same area of the retina at the same time, and any break in the fixation will produce noise in the map. Good retinotopic maps are usually obtained in highly motivated,



**Fig. 3.** Percentage of the surface occupied by the central  $\sim 2^\circ$  within the representation of the more peripheral  $\sim 10^\circ$  of the visual field in the group of subjects with autism (ASD) and normal controls. No difference can be seen between the two groups.

experienced subjects, and we were impressed by the reliability of the data produced by our subjects with autism. The nature of the stimuli can partly explain this: the stimuli, consisting of flickering expanding rings for eccentricity mapping, might have held a certain fascination for the subjects we scanned.

Individuals with autism have retinotopic maps in their visual cortex that are similar in all respects to those seen in controls in this study and in other studies. No difference was observed that could explain differences in visual processing of individuals with autism. We observed no difference between the representation of the center of the visual field (fovea) between participants with autism and control subjects. This observation indicates that the differences observed in local versus global processing in individuals with autism do not arise from early visual areas, but that they more likely have a basis in other areas of the brain that play a role in attention and cognition, such as the parietal or frontal cortex.

## CONCLUSION

Individuals with autism appear to have retinotopic maps similar to those of normal subjects, indicating that low-level visual processing is intact in high ability individuals with autism, and that social-communication deficits in autism are probably not the result of primary visuo-perceptual deficits.

## REFERENCES

- Carvill S. Sensory impairments, intellectual disability and psychiatry. *J Intellect Disabil Res* **45**, 467–483 (2001).
- Lockyer L and Rutter M. A five- to fifteen-year follow-up study of infantile psychosis. IV. Patterns of cognitive ability. *Br J Soc Clin Psychol* **9**, 152–163 (1970).
- Tymchuk AJ, Simmons JQ and Neafsey S. Intellectual characteristics of adolescent childhood psychotics with high verbal ability. *J Ment Defic Res* **21**, 133–138 (1977).
- Jolliffe T and Baron-Cohen S. Are people with autism and Asperger syndrome faster than normal on the Embedded Figures Test? *J Child Psychol Psychiatry* **38**, 527–534 (1997).
- Shah A and Frith U. An islet of ability in autistic children: a research note. *J Child Psychol Psychiatry* **24**, 613–620 (1983).
- Mottron L, Belleville S and Menard E. Local bias in autistic subjects as evidenced by graphic tasks: perceptual hierarchization or working memory deficit? *J Child Psychol Psychiatry* **40**, 743–755 (1999).
- Mottron L and Belleville S. A study of perceptual analysis in a high-level autistic subject with exceptional graphic abilities. *Brain Cogn* **23**, 279–309 (1993).
- O'Riordan MA, Plaisted KC, Driver J and Baron-Cohen S. Superior visual search in autism. *J Exp Psychol Hum Percept Perform* **27**, 719–730 (2001).
- Happe FG. Studying weak central coherence at low levels: children with autism do not succumb to visual illusions. A research note. *J Child Psychol Psychiatry* **37**, 873–877 (1996).
- Ropar D and Mitchell P. Are individuals with autism and Asperger's syndrome susceptible to visual illusions? *J Child Psychol Psychiatry* **40**, 1283–1293 (1999).
- Sasaki Y, Hadjikhani N, Fischl B, Liu AK, Marrett S, Dale AM *et al.* Local and global attention are mapped retinotopically in human occipital cortex. *Proc Natl Acad Sci USA* **98**, 2077–2082 (2001).
- Plaisted K, Swettenham J and Rees L. Children with autism show local precedence in a divided attention task and global precedence in a selective attention task. *J Child Psychol Psychiatry* **40**, 733–742 (1999).
- Ring HA, Baron-Cohen S, Wheelwright S, Williams SC, Brammer M, Andrew C *et al.* Cerebral correlates of preserved cognitive skills in autism: a functional MRI study of embedded figures task performance. *Brain* **122**, 1305–1315 (1999).
- Frith U. *Autism: Explaining the Enigma*. Oxford: Blackwell; 1989.
- Plaisted K. Reduced generalization in autism: an alternative to weak central coherence. In: Burack JA, Charman T, Yirmiya N and Zelazo PR (eds). *The Development of Autism: Perspectives from Theory and Research*. Hillsdale, NJ: Erlbaum; 2001, pp. 149–169.
- Sereno MI, Dale AM, Reppas JB, Kwong KK, Belliveau JW, Brady TJ *et al.* Borders of multiple visual areas in humans revealed by functional magnetic resonance imaging. *Science* **268**, 889–893 (1995).
- DeYoe EA, Carman GJ, Bandettini P, Glickman S, Wieser J, Cox R *et al.* Mapping striate and extrastriate visual areas in human cerebral cortex. *Proc Natl Acad Sci USA* **93**, 2382–2386 (1996).
- Tootell RB, Mendola JD, Hadjikhani NK, Ledden PJ, Liu AK, Reppas JB *et al.* Functional analysis of V3A and related areas in human visual cortex. *J Neurosci* **17**, 7060–7078 (1997).
- Hadjikhani N, Liu AK, Dale AM, Cavanagh P and Tootell RBH. Retinotopy and color selectivity in human visual cortical area V8. *Nature Neurosci* **1**, 235–241 (1998).
- WASI. *Wechsler Abbreviated Scale of Intelligence*. San Antonio, TX: The Psychological Corporation; 1999.
- Lord C, Rutter M and Le Couteur A. Autism Diagnostic Interview-Revised: a revised version of a diagnostic interview for caregivers of individuals with possible pervasive developmental disorders. *J Autism Dev Disord* **24**, 659–685 (1994).
- Lord C, Risi S, Lambrecht L, Cook EH Jr, Leventhal BL, DiLavore PC *et al.* The autism diagnostic observation schedule-generic: a standard measure of social and communication deficits associated with the spectrum of autism. *J Autism Dev Disord* **30**, 205–223 (2000).
- Dale AM, Fischl B and Sereno MI. Cortical surface-based analysis I: Segmentation and surface reconstruction. *NeuroImage* **9**, 179–194 (1999).
- DeYoe EA, Bandettini P, Neitz J, Miller D and Winans P. Functional magnetic resonance imaging (fMRI) of the human brain. *J Neurosci Methods* **54**, 171–187 (1994).
- Engel SA, Rumelhart DE, Wandell BA, Lee AT, Glover GH, Chichilnisky EJ *et al.* fMRI of human visual cortex. *Nature* **369**, 525 (1994).

Acknowledgements: This work was supported by grants DC-03610 to H. T.-F. and ROI NS44824-01 to N. H.